

Histological Evaluation of Local Application of Equisetum Arvense /Urtica Dioica Extract on Bone Healing in Rabbits

¹Suhail Labeeb Hasoon, MSc and ²Ban A. Ghani, PhD

^{1, 2}Department of Oral Diagnosis, College of Dentistry, University of Baghdad, Baghdad, Iraq.

Corresponding author: Suhail Labeeb Hasoon

E-mail: suhaillabeeb11@gmail.com

Received 20 May, 2023.

Accepted for publication on August 16, 2023.

Published March 20, 2024.

Doi: <https://doi.org/10.58827/187082jbqmm>

Abstract

Background Bone repair is a dynamic and intricate process that involves the coordinated actions of many different types of cells. Due to their minimal side effects, the use of medicinal herbs in bone mending has gained growing attention. The anti-inflammatory effects of Equisetum arvense (Eq) and Urtica dioica (UR) extract are utilized in traditional medicine to promote bone repair. **Objectives** This study aimed to evaluate the effect of locally applied Equisetum arvense and Urtica dioica on the bone healing process. **Materials and Methods** For this experiment, 24 adult male New Zealand rabbits were employed with an average weight between 1.5 and 2.0 kg. Each animal had four holes induced into both femurs, three of which were treated with Eq and UR extract separately and one was treated with a combination of both Eq and UR. The untreated hole served as a control. Scarifications of animals were done after 2 and 4 weeks of healing periods, 12 rabbits for each. Image J software processed Bone specimens for histological and histomorphometric analysis of osteoblasts, osteocytes, osteoclasts, trabecular number, trabecular area, and bone marrow space. **Results** Histological findings indicated that the bone defects in the Eq and UR showed more bone formation, mineralization, and maturation compared with the control group and the bone defects in combination groups showed more bone formation than that when the extracts were used solely. Multiple group differences for bone cells showed a highly significant difference among all groups in both healing periods. Highly significant results were obtained between both durations regarding trabecular area, trabecular number, and bone marrow area. **Conclusions** Findings of this study revealed that combined local application of (Eq,UR) extracts was more effective in enhancing bone regeneration and accelerating bone healing than the other groups.

Keywords: Equisetum Arvenus; Urtica Dioica; Bone healing.

Introduction

Bone is a tissue that is divided into the trabecular bone (also known as cancellous or spongy bone) and the cortical bone (also known as dense or compact bone) (Martins et al, 2018; Zamfirescu et al, 2020). The nanocomposite complex structure of bone comprises organic collagen nanofibers

and inorganic compounds like hydroxyapatite and whitlockite (Zhang, et al, 2018). Bone tissue is constantly changing due to the interplay between osteocytes (OC), osteoblasts (OB), and osteoclasts (OCL), which synthesize new bone and degrade old tissue, respectively. As a result, bone tissue is capable of remarkable

remodeling and repair. (Zarif, 2021) when small abnormalities arise (Sharma et al, 2020). The development of novel medicinal substances with the potential to stimulate bone regeneration and an understanding of the inflammatory mechanisms that govern this process have been major areas of research interest (Miranda et al, 2019). Because of their demonstrated ability to decrease bone resorption and tissue inflammation while simultaneously increasing antioxidant defenses, tissue vascularization, and bone cell proliferation, natural bio-compounds may be a cost-effective and safe alternative to pharmaceutical options for bone healing and regeneration (Suvarna et al, 2018). The significant reduction of the noticeable adverse effects of chemical agents has been made possible by the discovery of novel pharmacological targets made possible by the extraction and identification of bioactive compounds from plants. In the field of dermo pharmacy, plant extracts have a strong reputation for accelerating wound healing via many molecular mechanisms, including antioxidant and antibacterial activities (Thakur et al, 2011). In vitro, Eq stimulates the growth of osteoblasts while blocking the activity of destructive osteoclasts (Costa-Rodrigues, 2012). The purpose of this investigation was to compare the histological results of using EV/UR alone and in combination to promote bone repair.

Materials and Methods

The College of Dentistry at the University of Baghdad's guidelines for conducting animal studies were followed (Ref. No. 299, 1/4/2021). Ketamine hydrochloride (50 mg), xylazine (2%) (Both produced by Fabrique par Hemani international KEPZ Karachi-Pakistan), formalin (10%), ethanol alcohol (96%) (All produced by Fabrique par Hemani international KEPZ Karachi-Pakistan), xylol, paraffin wax, and hematoxylin and eosin (H&E) stain were used in this study. In this experiment, we employed 24 adult male New Zealand rabbits averaging 1.5-2 kg in weight. Three intra-bony holes, each 3 mm in diameter and 4 mm in depth were induced

into both femurs of each animal. All animals were randomly divided into two groups (12 animals for each healing periods 2 and 4 weeks).

Two intra bony holes were created in each femur which were treated as follows:

- 1- Group A: holes were left to heal spontaneously as control.
- 2- Group B: holes were filled with Eq extract (0.5 ml).
- 3- Group C: holes were filled with UR extract (0.5 ml).
- 4- Group D: holes filled with a combination of Eq and UR in a ratio of 1:1

Sacrificiation of animals was done to prepare specimens for routine histological procedures.

The following microarchitectures were measured. Osteoblasts (OB/mm²), osteoclasts (OCL/mm²), and osteocytes (OC/mm²). Trabecular number (TN /mm²), trabecular area (TA /mm²), and bone marrow area (BMA /mm²), using ImageJ. exe, an image processing tool developed by the National Institutes of Health and the Laboratory for Optical and Computational Instrumentation (LOCI), University of Wisconsin.

Results

Histological and histomorphometrical findings
 Two weeks period: numerous osteocytes are lodged in bone, and osteoblasts may be observed rimming bone as new bone trabeculae are deposited around marrow tissue in the control group (figure 1A). New bone trabeculae surrounded by osteoblasts and irregularly dispersed osteocytes embedded in bone marrow tissue are seen in this micrograph of a bone slice taken at the defect location of the UR group (figure 1B). - Bone sections taken from defect sites in the Eq group reveal newly created bone trabeculae entrapping osteocytes and rimmed by osteoblasts (figure 1C). Bone trabeculae surrounded by osteoblasts, osteoclast noticed, and a reversal line can be seen in a micrograph of the UR /Eq group (figure 1D).
 Four weeks period: In the micrograph of the bone section at the defect site of the control group the osteocytes are neatly arranged around the haversian canal,

and the canal itself is lined with osteoblasts, figure 2A. Mature bone, separated from basal bone by a reversal line rimmed by osteoblasts and osteoclasts, is seen in a micrograph of the UR group (figure 2B). Mature bone, with osteocytes seeming to be oriented around the Haversian canal, reversal line (figure 2C), can be seen in a micrograph of a bone segment taken at the defect location of the Eq group. Bone sections taken from the UR/Eq combination group after 4 weeks showed osteocytes around the Haversian canal, osteoblasts at the bone periphery, and osteoclasts residing in Howships lacuna (figure 2d). A microphotograph view of the UR group shows mature bone that is demarcated from basal bone by reversal line, osteocytes arranged around the haversian canal which is lined by osteoblasts (figure 2B). Microphotograph view of bone section at defect site of Eq group shows mature bone in which osteocytes appear arranged around the Haversian canal, reversal line (figure 2C). Histological examination of the bone section after 4 weeks of combination group (UR/Eq) shows thick dense new bone that is separated from basal bone by reversal line, osteocytes seen surrounding haversian canal, osteoblasts at the bone periphery and osteoclast (figure 2D). Histomorphometric findings. Bone cells: As shown in table1, mean values of OC increased with time in all studied groups and the highest values were recorded at 2 and 4 weeks duration for combination groups (UR/Eq). Regarding OCL their count decreased obviously with time it was higher at 2 weeks duration where the highest value was recorded with the C group, and the lowest values were detected with the combination group in both durations. Mean values of TN decreased with time and TA mean values increased with time as shown in (figure 3. A B C) while BMA showed a decrease in mean values in both durations in all studied groups. According to the ANOVA test, group comparison showed a highly significant difference ($P < 0.01$) found among control, Eq., UR. and Eq/UR groups for all the studied variables in both healing durations (2 and 4 weeks) except for TN at 4 weeks, in

which the result was not significant as shown in table 2. According to the ANOVA test, group comparison showed a highly significant difference ($P < 0.01$) found among control, Eq., UR. and Eq/UR groups for all the studied variables in both healing durations (2 and 4 weeks) except for TN at 4 weeks, in which the result was not significant as shown in table 2. Significant result ($P < 0.05$) was obtained between 2 and 4 weeks regarding TN in all groups except for the Eq group; the highly significant results were obtained ($P < 0.01$) while the highly significant results ($P < 0.01$) were obtained regarding TA and MA among all the studied groups by using paired T test shown in table 3.

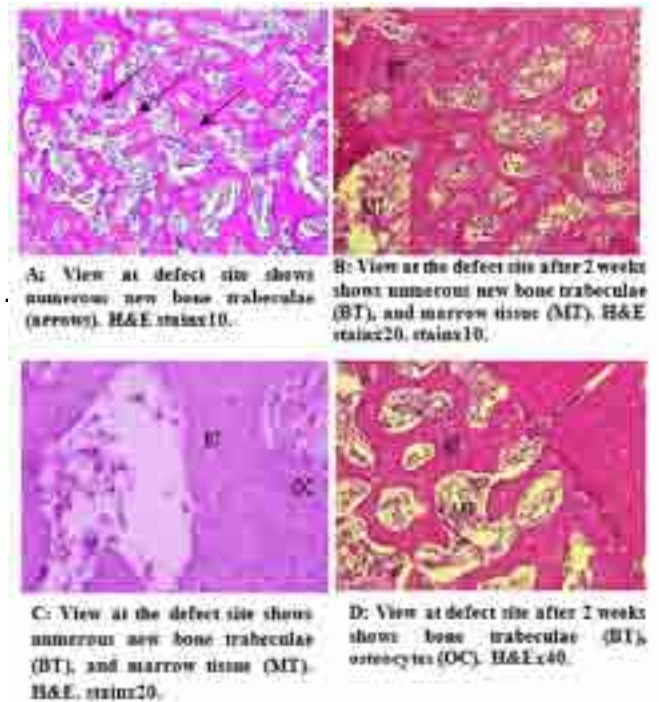


Figure (1): Two-weeks period of the experimental group.

Table (1): Descriptive values of the control, Eq., Ur. and mixture groups at different healing periods for bone cells, Baghdad, 2022.

Group	Time	OC	BC	OC/BC	OC	BC	OC/BC	OC	BC	OC/BC
Control	2 weeks	1.2	1.5	0.8	1.5	1.2	1.2	1.5	1.2	0.8
	4 weeks	1.5	1.8	1.2	1.8	1.5	1.5	1.8	1.5	1.2
Eq.	2 weeks	1.8	2.2	1.2	2.2	1.8	1.8	2.2	1.8	1.2
	4 weeks	2.2	2.8	1.5	2.8	2.2	2.2	2.8	2.2	1.5
Ur.	2 weeks	2.0	2.5	1.3	2.5	2.0	2.0	2.5	2.0	1.3
	4 weeks	2.5	3.0	1.5	3.0	2.5	2.5	3.0	2.5	1.5
Mixture	2 weeks	2.1	2.6	1.4	2.6	2.1	2.1	2.6	2.1	1.4
	4 weeks	2.6	3.2	1.6	3.2	2.6	2.6	3.2	2.6	1.6

Table (2): Group comparison for T no, T area and M area at 2 and 4 weeks, Baghdad, 2022.

Variable	Duration	Group comparison	
		F test	P value
T no.	2 weeks	21.266	0.000**
	4 weeks	2.111	0.066
T area	2 weeks	6.977	0.000**
	4 weeks	15.330	0.000**
M area	2 weeks	14.219	0.000**
	4 weeks	23.870	0.000**

Table (3): Duration comparison for Tno, Tarea and Marea in all studied groups, Baghdad, 2022.

Variable	Group	2 weeks	4 weeks	F test	P value
T no.	Control	1.2	1.5	21.266	0.000**
	Eq.	1.8	2.2	21.266	0.000**
T area	Control	1.5	1.8	6.977	0.000**
	Eq.	2.2	2.8	6.977	0.000**
M area	Control	1.2	1.5	14.219	0.000**
	Eq.	1.8	2.2	14.219	0.000**

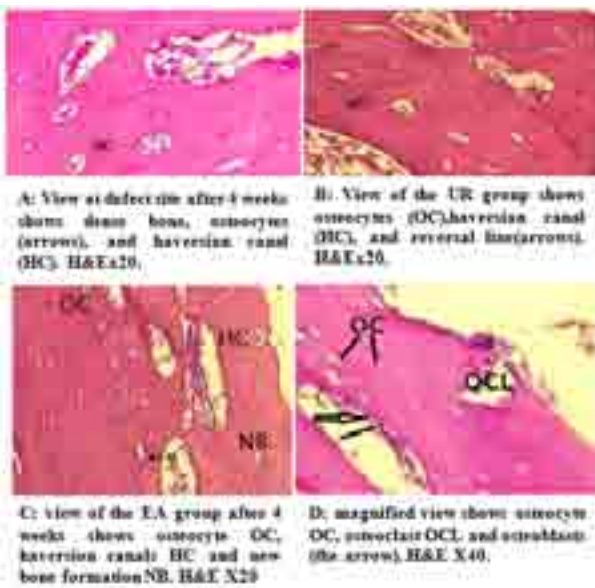


Figure (2): Four weeks duration.



Figure (3): Mean values of TN, TA and MA in the studied groups at 2 and 4 weeks.

Discussion

Bone healing is a complex regenerative process that the skeletal system undergoes to restore skeletal integrity (Von Minckwitz et al, 2018). Herbal medicament is a branch of developing medicine used for treating and caring for many injuries and wounds because plant extracts are extensively accessible with reduced side effects and efficient crUre preparations (Nezhad et al, 2013). Mean values of OB and OC were higher in experimental groups than in control they decreased with time, and OC increased with time indicating the accelerative effect of Eq and UR extracts on bone deposition and mineralization. in agreement with Pereira et al, (2012), who found that Eq extract elicited inductive effects on human osteoblasts while inhibiting the activity of *S. aureus*, suggesting a potentially interesting profile regarding bone regeneration strategies. Also supported by a previous study that Eq have the highest silica content that helps in the absorption and utilization of calcium and synthesis and stabilization of collagen by prolyl

hydroxylase enzyme it enhances the proliferation of osteoblasts and inhibits osteoclasts in vitro (Kotwal et al, 2014). Arbabzadegan et al, (2019) stated that silica content and other ingredients found in the Eq may explain the highly significant increase in osteoblasts and osteocytes due to acceleration in bone formation by the beneficial effect of plant extract. In the case of using UR, the results showed a significant increase in osteoblast and osteocyte with a decrease in osteoclast in both periods in agreement with Irgin et al, (2016), who examined bone formation in intermaxillary suture after systemic administration of UR. Moreover, (Upton, 2013) studied the chemical composition of UR and reported that its leaves contain a wide variety of chemical constituents such as minerals, vitamins, amino acids, flavonoids, sterols, phenolics, and fatty acids, which have beneficial effects on human health, which supports findings of this study. The increased mean values of osteoblasts and osteocytes have been reported in a previous study where the local application of punica granatum seed oil for bone repair was evaluated (Ibrahim and Ghani, 2022). The bone healing process is indicated by the deposition of bone matrix and the creation of trabecular bone, which decreases in number but grows in thickness throughout the healing process. The amount of newly formed bone formation in osseous defects is one of the most critical elements in determining the degree of bone regeneration in these defects (Pepelassi et al, 2019). In this study, different microscopic features that were observed in the bone sections of different study groups may be explained according to (Calori et al, 2008), who reported that variations in the body's response to genetic or environmental factors, including the exogenous application of materials that contain bone-stimulating agents, causing new bone formation in the defect site. Regarding TN, TA and MA the detected results showed number of new bone trabeculae, trabecular area and bone marrow space area showed higher mean values in combination groups than others. Highly significant differences between groups were

observed in all histomorphometric parameters throughout all durations. agreed with (Costa pinto et al, 2011; Bohner et al, 2020; Almashhadi and Al-Ghaban, 2022). The assessment of TN and MA showed the highest mean values recorded at 2 weeks while TA showed the highest values at 4 weeks noticed more obviously in the combination group in line with (Majeed and Ghani, 2018; AL-Ghaban and Jassem, 2020), who studied the effect of local application of flavonoid hibiscus sabdariffa on experimentally induced bone.

Conclusions

Defect sites treated by Eq/UR separately and in combination promote and accelerate the bone healing process by enhancing early bone formation and maturation.

References

- Kotwal SD, Badole SR. Anabolic therapy with Equisetum arvense along with bone mineralising nutrients in ovariectomized rat model of osteoporosis. *Indian J Pharmacol.* 2016 May-Jun;48(3):312-5. [https://doi: 10.4103/0253-7613](https://doi.org/10.4103/0253-7613)
- Calori GM, Tagliabue L, Gala L, d'Imporzano M, Peretti G, Albisetti W. Application of rhBMP-7 and platelet-rich plasma in the treatment of long bone non-unions: a prospective randomised clinical study on 120 patients. *Injury.* 2008 Dec;39(12):1391-402. [https://doi: 10.1016/j.injury.2008.08.011](https://doi.org/10.1016/j.injury.2008.08.011)
- Costa-Pinto AR, Reis RL, Neves NM. Scaffolds based bone tissue engineering: the role of chitosan. *Tissue Eng Part B Rev.* 2011 Oct;17(5):331-47. [https://doi: 10.1089/ten.teb.2010.0704](https://doi.org/10.1089/ten.teb.2010.0704). Epub 2011 Aug 2.
- Costa-Rodrigues J, Carmo SC, Silva JC, Fernandes MH. Inhibition of human in vitro osteoclastogenesis by Equisetum arvense. *Cell Prolif.* 2012 Dec;45(6):566-76. [https://doi: 10.1111/j.1365-2184.2012.00848.x](https://doi.org/10.1111/j.1365-2184.2012.00848.x)
- Ibrahim Fouad Mohamed,¹ Ban A. Ghani,¹

and Abdalbseet A. Fatalla, (2022). Histological Evaluation of the Effect of Local Application of Punica granatum Seed Oil on Bone Healing. *International Journal of Biomaterial*, 2022:1-8. <https://doi.org/10.1155/2022/4266589>

Irgin C, Çörekçi B, Ozan F, Halicioğlu K, Toptaş O, Birinci Yildirim A, Türker A, Yılmaz F. Does stinging nettle (*Urtica dioica*) have an effect on bone formation in the expanded inter-premaxillary suture? *Arch Oral Biol*. 2016 Sep;69:13-8. [https://doi: 10.1016/j.archoralbio.2016.05.003](https://doi.org/10.1016/j.archoralbio.2016.05.003)

Martins, J.P.; Ferreira, M.P.A.; Ezazi, N.Z.; Hirvonen, J.T.; Santos, H.A.; Thirvikraman, G.; França, C.M.; Athirasala, A.; Tahayeri, A. Chapter 4—3D printing: Prospects and challenges. In *Nanotechnologies in Preventive and Regenerative Medicine*; Uskoković, V., Uskoković, D.P., Eds.; Elsevier: Amsterdam, The Netherlands, 2018; pp. 299–379.

Miranda, L.L.; Guimarães-Lopes, V.d.P.; Altoé, L.S.; Sarandy, M.M.; Melo, F.C.S.A.; Novaes, R.D.; Gonçalves, R.V. Plant Extracts in the Bone Repair Process: A Systematic Review. *Mediat. Inflamm*. 2019, 2019, 1296153.

Nada M.H. AL-Ghaban and Ghazwan H. Jasem Histomorphometric evaluation of the effects of local application of red clover oil (*trifolium pratense*) on bone healing in rats. *J Bagh College Dentistry* Vol. 32(2), June 2020. <https://doi.org/10.26477/jbcd.v32i2.2891>

NazaninArbabzadegan, AliAkbar, Moghadamnia, Sohrab Kazemi, Babol University of Medical Sciences, Original Article Effect of equisetum arvense extract on bone mineral density in Wistar rats via digital radiography, June 2019, *Caspian Journal of Internal Medicine* 10(2):176-182. <https://doi.org/10.22088/cjim.10.2.176>

Nezhad A1, Michael F Holick, Vitamin D for health: a global perspective, 2013 Jul;88(7):720-55. <https://doi.org/10.1016/j.mayocp.2013.05.011>

Pepelassi E, Perrea D, Dontas I, Ulm C, Vrotsos I, Tangl S. Porous Titanium Granules in comparison with Autogenous Bone Graft in Femoral Osseous Defects: A Histomorphometric Study of Bone Regeneration and Osseointegration in Rabbits. *Biomed Res Int*. 2019 Dec 14;2019:8105351. [https://doi: 10.1155/2019/8105351](https://doi.org/10.1155/2019/8105351)

Bessa Pereira C, Gomes PS, Costa-Rodrigues J, Almeida Palmas R, Vieira L, Ferraz MP, Lopes MA, Fernandes MH. Equisetum arvense hydromethanolic extracts in bone tissue regeneration: in vitro osteoblastic modulation and antibacterial activity. *Cell Prolif*. 2012 Aug;45(4):386-96. [https://doi: 10.1111/j.1365-2184.2012.00826.x](https://doi.org/10.1111/j.1365-2184.2012.00826.x)

Sharma, A.; Sharma, P.K.; Malviya, R. Stimuli-responsive supramolecules for bone tissue engineering. *Biointerface Res. Appl. Chem*. 2020, 10, 5122–5127.

Sura Saad Majeed, Ban A. Ghani. *J Bagh College Dentistry*. Effect of Topical Application of Flavanoids Extract of Hibiscus Sabdariffa on Experimentally Induced Bone Defect. (2018), 30(1), 2018. <https://doi.org/10.12816/0046309>

Suvarna V, Sarkar M, Chaubey P, Khan T, Sherje A, Patel K, Dravyakar B. Bone Health and Natural Products- An Insight. *Front Pharmacol*. 2018 Sep 19;9:981. [https://doi: 10.3389/fphar.2018.00981](https://doi.org/10.3389/fphar.2018.00981).

Thakur, R 1, * Nitika Jain, 1 Raghvendra Pathak, 1 and Sardul Singh Sandhu 2 Practices in Wound Healing Studies of Plants. *Evid Based Complement Alternat Med*. 2011; 2011: 438056. Published online 2011 May 26. [https://doi: 10.1155/2011/438056](https://doi.org/10.1155/2011/438056)

Upton R., "Stinging nettles leaf (*Urtica dioica* L.): Extraordinary vegetable medicine," *Journal of Herbal Medicine*, vol. 3, no. 1, pp. 9–38, 2013.

von Minckwitz G, Procter M, de Azambuja E, Zardavas D, Benyunes M, Viale G, Suter T,

Arahmani A, Rouchet N, Clark E, Knott A, Lang I, Levy C, Yardley DA, Bines J, Gelber RD, Piccart M, Baselga J; APHINITY Steering Committee and Investigators. Adjuvant Pertuzumab and Trastuzumab in Early HER2-Positive Breast Cancer. *N Engl J Med.* 2017 Jul 13;377(2):122-131. [https:// doi: 10.1056/NEJMoa1703643](https://doi.org/10.1056/NEJMoa1703643).

Zainab Abdul-Jabbar Almashhadi, Nada M.H. AL-Ghaban. Histological and immunohistochemical evaluation of transforming growth factor- β 3 on bone healing treated by combination of chitosan and betatricalcium phosphate in rabbits. *Journal of Research in Medical and Dental Science* Volume 10, Issue 7. 2022.

Zamfirescu, A.I.; Banciu, A.; Banciu, D.; Jinga, S.I.; Busuioc, C. Composite Fibrous Scaffolds Designed for Bone Regeneration. *Rev. Romana De Mater. Rom. J. Mater.* 2020, 50, 161–165. 5.

Zarif, M.-E. A review of chitosan-, alginate-, and gelatin-based biocomposites for bone tissue engineering. *Biomater. Tissue Eng. Bull.* 2018, 5, 97–109. *Materials* 2021, 14, 1867 17 of 20 7.

Zhang, J.; Esa, A.; Jang, H.L.; Khademhosseini, A. Chapter 29—Applications of Nanotechnology for Regenerative Medicine; Healing Tissues at the Nanoscale. In *Principles of Regenerative Medicine*, 3rd ed.; Atala, A., Lanza, R., Mikos, A.G., Nerem, R., Eds.; Academic Press: Boston, MA, USA, 2019; pp. 485–504.